

# How Mainstream Medicine Sees Photodynamic Therapy in the United Kingdom

Presented by Stephen G. Bown, MD, FRCP, *University College London, United Kingdom*

## Abstract

Although photodynamic therapy (PDT) has been used successfully to treat an assortment of different types of cancer, it has yet to reach the level of mainstream medicine on either side of the Atlantic. Unsubstantiated claims of PDT's efficacy in the past may be part of the reason for this. However, perhaps the main obstacle to PDT's endorsement by conventional medicine is the limited number of high-quality randomized controlled trials (RCTs) comparing it with relevant comparators for all meaningful outcomes, including effectiveness, safety, adverse events, quality of life, survival, and cost. Based on a Health Technology Assessment report on the current status of PDT and consultation with professional groups, specialist societies, and clinical study groups in the United Kingdom, this article explores the current clinical guidelines for use of PDT in cancer treatment and the dearth of supportive data from RCTs. (*JNCCN* 2012;10[Suppl 2]:S69–S74)

“It is an ongoing struggle to establish photodynamic therapy [PDT] as a mainstream therapeutic option,” declared Stephen G. Bown, MD, FRCP, Director of the National Medical Laser Centre and Professor of Laser Medicine and Surgery at University College London. “We would all like to see PDT in widespread, routine clinical use in a range of specialties, but it is not happening,” he admitted. In an attempt to understand why the progress with PDT has been so slow, Dr. Bown first

explored the obstacles blocking the way for PDT into conventional medicine. He then addressed the current status of PDT use in the United Kingdom for skin, lung, esophageal, head and neck, bile duct, and brain cancers based on a 2010 Health Technology Assessment (HTA) report (available at [www.hta.ac.uk/1854](http://www.hta.ac.uk/1854))<sup>1</sup>; consensus opinions from professional groups, specialist societies, and clinical study groups; and scant data from the literature. The bottom line is that, outside of dermatology, PDT in oncology is not yet a strongly evidence-based treatment and well-constructed, international collaborative clinical trials are sorely needed to support the wealth of clinical experience with PDT and to confirm its effectiveness compared with established options in treating other types of cancers.

At the top of the list of obstacles to the mainstream use of PDT is the lack of adequate evidence of safety and efficacy compared with alternative treatments for various conditions, stated Dr. Bown. Randomized controlled trials (RCTs) may be at the heart of the problem and also the key to the solution. Next, the regulatory processes may also represent a stumbling block for PDT. “The hurdles of the regulatory process are just as bad on each side of the Atlantic,” acknowledged Dr. Bown. The fact that PDT is not easily categorized represents perhaps another issue in terms of the problem of conservatism of the medical profession. “PDT does not quite fit with radiation or surgery,” he added. Lack of education about the true nature of PDT is yet another obstacle, as is commercial support. Finally, unsubstantiated claims made by early PDT clinicians about its efficacy in cancer treatment are now causing many mainstream medical professionals to be sceptical about its current more realistic achievements, said Dr. Bown.

Presented by Stephen G. Bown, MD, FRCP, Director, National Medical Laser Centre; Professor of Laser Medicine and Surgery, University College London, United Kingdom.

Dr. Bown participates in PDT prostate research sponsored by Steba Biotech, and is (unpaid) director of the International Photodynamic Association (IPA).

Correspondence: Stephen G. Bown, MD, FRCP, University College, 67-73 Riding House Street, London W1W 7EJ England. E-mail: [s.bown@ucl.ac.uk](mailto:s.bown@ucl.ac.uk)

Bown

## HTA Report: Many References, Few Evaluable Trials

Several years ago, the National Health Service (NHS) commissioned an HTA report on the current status of PDT in the United Kingdom. The HTA program produces high-quality research information on the effectiveness, cost, and broader impact of health technologies for those who use, manage, and provide care in the NHS. Similar to Cochrane reports, revealed Dr. Bown, the HTA report was written by an independent group at the University of York, Centre for Reviews and Dissemination.

To establish the effectiveness of new treatments in relation to existing conventional therapies, the report planned to include only data from PDT trials with comparators in the treatment of skin, lung, head and neck, esophageal, bile duct, and brain cancers.<sup>1</sup> Of the 12,522 total references identified, only 699 were potentially relevant. Of the 88 evaluable trials, half focused on PDT for skin conditions. RCTs were assessed for the skin conditions and Barrett esophagus, whereas nonrandomized trials were evaluated for all of the other sites. “So here we are beginning to understand where mainstream medicine is making a fuss about our shouting too loud about PDT,” admitted Dr. Bown.

**Table 1 Professional Organizations Consulted for the United Kingdom Photodynamic Therapy Report**

### Specialist societies

- Cancer Research (United Kingdom)
- The British Association of Dermatologists
- The British Association of Head & Neck Oncologists
- The British Thoracic Society
- The British Society of Gastroenterology
- The Society of British Neurological Surgeons
- National Cancer Research Network (NCRN) clinical study groups
  - Brain Tumour Group
  - Melanoma Group
  - Head & Neck Cancer Group
  - Lung Cancer Group
  - Upper Gastrointestinal Cancer Group

### Report written by photodynamic therapy experts from:

- International Photodynamic Association (IPA)
- British Medical Laser Association (BMLA)
- European Platform for Photodynamic Medicine (EPPM)

Published in 2010, the HTA report found that many of the PDT indications and optimal parameters had not been adequately identified and that high-quality trials are needed to compare PDT with relevant comparators for all meaningful outcomes (effectiveness, safety, adverse events, quality of life, survival, and cost). In addition, quality studies from the patient perspective were necessary. If RCTs were not possible with PDT, alternative forms of study would have to be considered and devised. The HTA report concluded that PDT was an active area of research.

Based on the HTA report, the United Kingdom government determined that good evidence supports the efficacy of PDT in skin cancer and precancer and possibly Barrett esophagus, but only poorly documented results were available for most of the other oncologic indications. A workshop of PDT clinicians in the United Kingdom was called for to assess the value of “observational” publications. Moreover, the Department of Health report on the workshop would be drafted by clinicians using PDT in the United Kingdom, and the results would be shared with nonexperts in PDT from relevant specialty organizations. Table 1 lists the specialist societies and clinical study groups from the National Cancer Research Network that were consulted. This consensus report is still ongoing, revealed Dr. Bown.

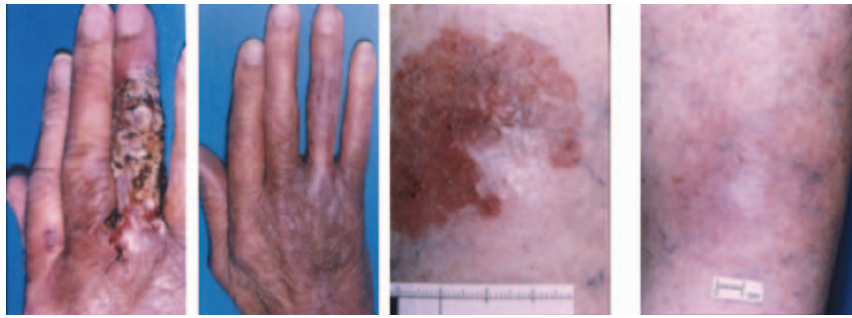
## Consensus on the Use of PDT by Organ Site

### Skin Conditions

The HTA report on the use of PDT for skin conditions indicated that PDT may be as effective as alternatives for actinic keratosis, Bowen disease, and superficial basal cell carcinoma (BCC).<sup>2-3</sup> However, the possibility of a treatment bias should be considered, because few blinded trials were available. For Bowen disease, PDT may achieve particularly good cosmetic results (Figure 1).

The professional dermatologic societies generally accepted the value of PDT for actinic keratosis, Bowen disease, and superficial BCC, but had some reservations about its use for nodular BCC, stated Dr. Bown. They also suggested that PDT may be useful in organ transplant recipients who are at high risk of developing skin malignancies, although this indication is still in an early stage of research. Two concerns emphasized that lesion clearance is more important than cos-

## PDT in the United Kingdom



**Figure 1** Before and after views of the use of 5-aminolevulinic acid (ALA)-mediated photodynamic therapy for the treatment of Bowen disease. Reprinted with permission from Ibbotson S. Photodynamic therapy. In: Ferguson J, Dover J, eds. *Photodermatology*. Manson Publishing, London 2006:125–134.

mesis and that simple excision is less expensive than PDT. One last recommendation was that PDT should be available only to multidisciplinary teams.

### Lung Cancer

The HTA report on PDT for lung cancer was based on no trials with comparators for early-stage disease and 7 trials with comparators (none since 2002) for advanced-stage disease.<sup>4</sup> All of the studies in advanced lung cancer were considered to be of poor quality. Three of them compared PDT with a neodymium:yttrium-aluminum-garnet (NdYAG) laser, and 2 compared radiotherapy with radiotherapy plus PDT; in the latter 2, a possible benefit was seen in the PDT group.

In terms of PDT for preinvasive and early invasive cancers in major airways,<sup>5</sup> “We all have seen some beautiful results, particularly from Dr. Kato in Japan and from here in Columbus, Ohio, but how does it fit in with everything else,” asked Dr. Bown. And which patients with lung cancer are suitable for PDT?

The professional lung cancer groups stated that PDT is appropriate for early-stage localized lung cancer, either primary or metachronous, if no alternative therapy is available. For advanced-stage lung cancer, they added that PDT may be possible, although it has no real advantages over alternatives, and it is rarely used. “We have heard of exciting results about PDT in advanced cancers about the potential for stimulating immunologic effects,” mentioned Dr. Bown, but no supportive study data yet show it is better than the alternatives. A formal trial comparing PDT with active surveillance for high-grade dysplasia may be worthwhile. Furthermore, a national register for long-term follow-up with PDT is recommended.

### Esophageal Cancer

The HTA report identified 11 randomized studies of PDT for dysplasia/intramucosal cancer in BE. The most useful data came from one study that showed a significant reduction in the risk of cancer with PDT.<sup>6</sup> Although only 5 small studies, none an RCT, were available for early esophageal cancer (invasive disease with no lymphatic tumor spread), “There may be a case for PDT in such patients who are not fit for definitive therapy,” stated Dr. Bown. For advanced-stage esophageal cancer, 7 palliative studies with comparators were found. However, there was a lack of comparability between the treatment arms and a lack of detail about the procedures, making it difficult to draw firm conclusions.

“PDT has worked very nicely in the esophagus for high-grade dysplasia,” declared Dr. Bown. Figure 2 illustrates the squamous regeneration and eradication of dysplasia with PDT for Barrett esophagus.

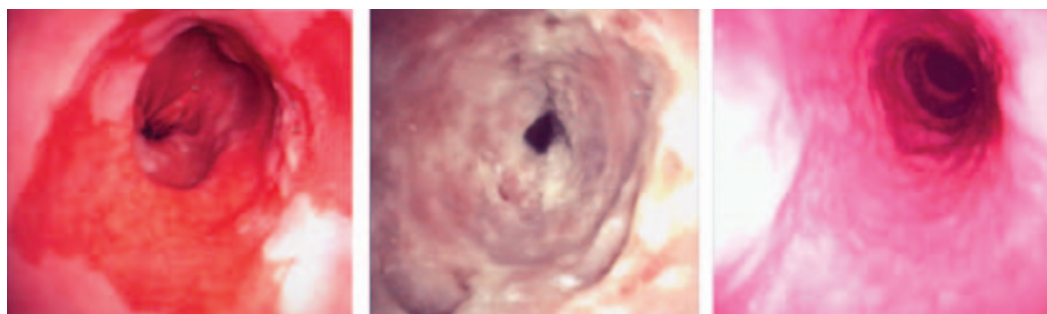
The professional gastrointestinal groups indicated that PDT for high-grade dysplasia/intramucosal carcinoma in Barrett esophagus is an approved treatment, although most centers may prefer to use radiofrequency ablation (RFA). “In the United Kingdom, PDT and RFA are essentially equal in terms of efficacy,” Dr. Bown noted. For early invasive cancer, PDT may be acceptable for high-risk patients with no other options, but RCTs are needed. PDT also may be an acceptable option for palliation of advanced cancers, but alternatives are usually preferred.

### Head and Neck Cancer

PDT for head and neck cancer is “one of the more contentious indications,” according to Dr. Bown. The HTA report located only 4 studies that included comparators, with 276 patients. However, 3 of them



Bown



**Figure 2** Photodynamic therapy (PDT) to treat Barrett esophagus. (Left) View before therapy. (Center) View 1 day after PDT showing necrosis of the esophageal mucosa. (Right) View 1 month after PDT showing regeneration of the squamous tissue and eradication of dysplasia.

were nonrandomized, appearing in abstract form only, and compared different aspects of PDT.

“We know it works beautifully on small lesions in the mouth,” stated Dr. Bown, with a “superb” cosmetic result as shown in Figure 3. In addition, PDT has been used for cancer of the base of the tongue that has failed to respond to radiotherapy, he added. “These patients could be facing 10 hours in the operating theater,” with subsequent difficulties with speaking, swallowing, and chewing; with PDT, “there is much less loss of function and a shorter recovery time,” according to Dr. Bown.

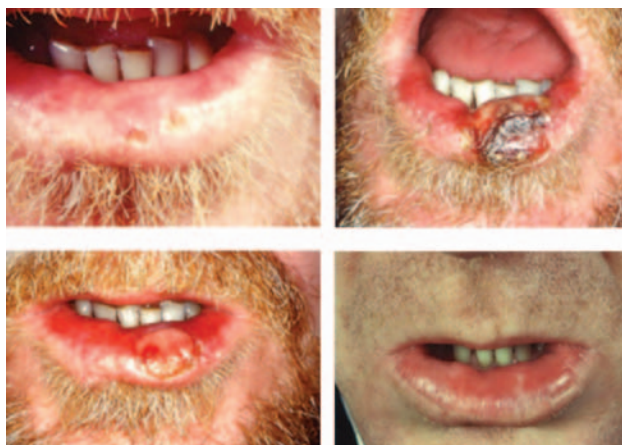An extensive observational multicenter experience with PDT for early mouth disease has been published.<sup>7</sup> In 121 patients, Hopper et al<sup>7</sup> showed a 90% complete response rate for PDT alone for T1 disease. Turning to laryngeal and oral cancers, Biel<sup>8</sup> achieved a cure rate with a single PDT treat-

ment of 91% for early laryngeal cancers and 94% for oral cancers. However, the statement from the professional groups called PDT “an unproven treatment for early disease of the head and neck and so currently should be limited to centers undertaking clinical trials.” They did admit that, based on the observational evidence, PDT may be of clinical value for those unsuitable for surgery. Dr. Bown said that the role of PDT in oral cancers can be answered definitively only in appropriate RCTs of equivalence studies, such as with PDT versus surgery for early oral disease and PDT versus laser excision or surveillance for laryngeal dysplasia.

### Bile Duct

Based on the HTA report, 2 RCTs<sup>9,10</sup> and 2 nonrandomized studies<sup>11,12</sup> compared stenting alone with stenting plus PDT for cancer of the bile duct. The evidence suggested that survival increased when PDT was given along with stenting.

Two other publications that appeared after the HTA report demonstrated conflicting results. Based on their review, Kiesslich et al<sup>13</sup> reported an average survival of 14 to 16 months with PDT plus biliary drainage for nonresectable hilar biliary tract cancer, compared with approximately 6 months for drainage alone. However, in the one negative RCT of PDT for cholangiocarcinomas and other biliary tract tumors, Pereira et al<sup>14</sup> showed longer survival in those treated with stenting alone than in those treated with stenting plus PDT (8.5 months vs 5.6 months). Finally, even more recently, Tomizawa and Tian<sup>15</sup> concluded that PDT could be regarded as a standard palliative therapy for unresectable cholangiocarcinoma, although the National Cancer Research Network (NCRN) dismissed these findings as being nonequivalent to those from a prop-



**Figure 3** Photos of 2 small cancers on the lip before (top left), 4 days after photodynamic therapy (PDT; top right), 14 days after PDT (bottom left), and a month after (bottom right). Reprinted from Grant et al, *Int J Cancer* 1997;71:937–942; with permission.

erly conducted National Cancer Research Institute (NCRI) study.

### Brain

“Unfortunately, the evidence we have seen on glioma so far is not very convincing,” Dr. Bown admitted. The HTA report noted 2 RCTs with PDT, both of which were stopped early because no evidence of efficacy was seen. Although one recent small study (of 27 patients) did suggest PDT conferred a benefit for brain cancer,<sup>16</sup> the consensus of the professional societies was that PDT should not be used outside clinical trials for glioma. They also indicated that although fluorescence-guided resection may increase the completeness of tumor resection, it does not improve survival.

### Current Recommendations and Future Directions

The National Institute for Health and Clinical Excellence (NICE) issues treatment guidelines for the United Kingdom. “NICE looks at all the data available, RCTs, and nonrandomized trials, whatever source, and takes a commonsense view of where clinical practice should go,” revealed Dr. Bown.

PDT is a NICE-approved treatment option for actinic keratosis, Bowen disease, and BCC, and is available at most major dermatologic centers in the United Kingdom. Another approved indication for PDT is for localized inoperable endobronchial cancer (early primary or metachronous disease). PDT is an approved treatment for high-grade dysplasia/Barrett esophagus, and is equally effective as RFA, although most centers now use RFA. For early esophageal cancer, PDT is available in a few specialized centers, but more data are needed to confirm its use in these patients. For advanced esophageal cancer, PDT is approved but rarely used, according to Dr. Bown. Still a controversial but particularly promising indication, PDT for head and neck cancers is used in a few specialized centers. For palliative therapy for unresectable cholangiocarcinoma, PDT is not currently used in the United Kingdom. Currently, PDT is being used for brain cancer only in RCTs.

“We can’t yet say, with our hands on our hearts, that outside dermatology, PDT in oncology is a strongly evidence-based treatment,” Dr. Bown admitted.

To move PDT forward, several steps are necessary, stated Dr. Bown. First, all dermatology departments with a multidisciplinary team should have ac-

cess to a PDT service. Second, more complex PDT services would best be provided by a small number of specialist centers, perhaps “a half a dozen centers around the United Kingdom and 20 or so in the United States,” he suggested. Third, one national center should be established to coordinate the provision of regional services and multicenter international trials. Furthermore, strong cohesive leadership to bring together the global PDT experience is essential, as is outstanding managerial expertise to fund and run the clinical trials needed to establish the most promising indications. Finally, measures to educate both the public and the medical profession about PDT are crucial to its movement into mainstream medicine.

In closing, Dr. Bown briefly shared an outstanding example of the type of RCT needed for all potential PDT indications. An internationally collaborated RCT is comparing PDT and active surveillance for low-risk cancer confined to the prostate gland and aims to recruit 400 patients, with participating centers from the United Kingdom, France, Holland, Belgium, Italy, and Germany. A comparable study is planned for Canada and the United States. This research program, driven by a commercial sponsor, may serve as a prototype of the type of proper RCT needed to define the emerging role of PDT in the treatment of cancer.

### Conclusion

PDT faces several obstacles, some more insurmountable than others, in its quest to join mainstream medicine. Based on the current accumulation of clinical data, sound evidence exists that PDT is an effective therapeutic alternative for certain skin conditions. In addition, it may play a role in the treatment of early localized lung cancer, high-grade dysplasia/intramucosal cancer in Barrett esophagus and advanced head and neck cancer. Beyond these indications, PDT has much promise and many clinical success stories, but high-quality, international collaborative RCTs comparing it with relevant conventional therapies for all meaningful outcomes are the key to its coming of age in oncology.

### References

1. Fayter D, Corbett M, Heirs M, et al. A systematic review of photodynamic therapy in the treatment of pre-cancerous skin conditions, Barrett’s oesphagus and cancers of the biliary tract, brain, head and neck, lung, oesophagus and skin. *Health Technol*

Assess 2010;14:1–288.

2. Attili SK, Ibbotson SH. How we treat Bowen's disease with topical photodynamic therapy in Dundee. *Photodiagnosis Photodyn Ther* 2009;6:41–45.
3. Morton CA, McKenna KE, Rhodes LE. Guidelines for topical photodynamic therapy: update. *Br J Dermatol* 2008;159:1245–1266.
4. Moghissi K, Dixon K, Stringer M, et al. The place of bronchoscopic photodynamic therapy in advanced unresectable lung cancer: experience of 100 cases. *Eur J Cardiothorac Surg* 1999;15:1–6.
5. Kennedy TC, McWilliams A, Edell E, et al. Bronchial intraepithelial neoplasia/early central airways lung cancer: ACCP evidence-based clinical practice guidelines (2nd edition). *Chest* 2007;132(Suppl):221S–233S.
6. Overholt BF, Lightdale CJ, Wang KK, et al. Photodynamic therapy with porfimer sodium for ablation of high-grade dysplasia in Barrett's esophagus; international, partially blinded, randomized phase III trial. *Gastrointest Endosc* 2005;62:488–498.
7. Hopper C, Kübler A, Lewis H, et al. mTHPC-mediated photodynamic therapy for early oral squamous cell carcinoma. *Int J Cancer* 2004;111:138–146.
8. Biel MA. Photodynamic therapy treatment of early oral and laryngeal cancers. *Photochem Photobiol* 2007;83:1063–1068.
9. Ortner ME, Caca K, Berr F, et al. Successful photodynamic therapy for unresectable cholangiocarcinoma: a randomized prospective study. *Gastroenterology* 2003;125:1355–1363.
10. Zoepf T, Jakobs R, Arnold JC, et al. Palliation of nonresectable bile duct cancer: improved survival after photodynamic therapy. *Am J Gastroenterol* 2005;100:2426–2430.
11. Kahaleh M, Mishra R, Shami VM, et al. Unresectable cholangiocarcinoma: comparison of survival in biliary stenting alone versus stenting with photodynamic therapy. *Clin Gastroenterol Hepatol* 2008;6:290–297.
12. Matull WR, Dhar DK, Ayaru L, et al. R0 but not R1/R2 resection is associated with better survival than palliative photodynamic therapy in biliary tract cancer. *Liver Int* 2011;31:99–107.
13. Kiesslich T, Neureiter D, Wolkersdörfer GW, et al. Advances in photodynamic therapy for the treatment of hilar biliary tract cancer. *Future Oncol* 2010;6:1925–1936.
14. Pereira S, Hughes SK, Roughton M, et al. Photostent-02: porfimer sodium photodynamic therapy plus stenting versus stenting alone in patients (pts) with advanced or metastatic cholangiocarcinomas and other biliary tract tumours (BTC): a multicentre, randomised phase III trial. Presented at the 2010 European Society for Medical Oncology (ESMO) Congress; October 8–12, 2010; Milan, Italy. Abstract 802O.
15. Tomizawa Y, Tian J. Photodynamic therapy for unresectable cholangiocarcinoma. *Dig Dis Sci* 2012;57:274–283.
16. Eljamel S. Photodynamic applications in brain tumors: a comprehensive review of the literature. *Photodiagnosis Photodyn Ther* 2010;7:76–85.